© 2021 EDIZIONI MINERVA MEDICA
Online version at http://www.minervamedica.it

Acta Phlebologica 2021 mese;22(0):000–000
DOI: 10.23736/S1593-232X.21.00495-1

CASE REPORT

Pulmonary embolic episode after hybrid treatment with endovascular laser ablation combined with polidocanol foam sclerotherapy

Juan CIFUENTES [1], Jorge H. ULLOA [2] *, Valentin FIGUEROA [3], Jose ORDOÑEZ [1], Ana MONTENEGRO [4], Camilo BARRAGAN [5]

[1]Faculty of Medicine, University of Los Andes, Bogotá, Colombia; [2]Department of Vascular Surgery, Faculty of Medicine, University Hospital of Fundación Santa Fe de Bogotá, University of Los Andes, Bogotá, Colombia; [3]Department of Physics, University of Los Andes, Bogotá, Colombia; [4]Department of Vascular Medicine, Faculty of Medicine, University Hospital of Fundación Santa Fe de Bogotá, University of Los Andes, Bogotá, Colombia; [5]Department of Interventional Radiology, University Hospital of Fundación Santa Fe de Bogotá, Bogotá, Colombia

*Corresponding author: Jorge H. Ulloa, Department of Vascular Surgery, Faculty of Medicine, University Hospital of Fundación Santa Fe de Bogotá, University of Los Andes, Carrera 7 N. 117-15, 110111 Bogotá, Colombia. E-mail: cirugiavascular@yahoo.com

ABSTRACT

Foam sclerotherapy and endovenous laser ablation are minimally-invasive techniques that have demonstrated safety and effectiveness for the treatment of chronic venous insufficiency. However, some extremely rare adverse events might take place. We report an uncommon case of a 38-year-old woman who developed pulmonary embolism after performing hybrid treatment that combines laser and foam sclerotherapy in the great saphenous vein. Three days after the intervention, the patient developed fever, dyspnea, malaise, inspirational chest pain, tachypnea and oxygen desaturation. A computed tomography angiography confirmed the suspected diagnosis of pulmonary embolism. A venous Duplex scan of the lower limbs showed no thrombi in the superficial nor the deep venous system, and no signs of deep venous thrombosis were found in the leg examination. A hypercoagulable disorders screening indicated a previously silent antiphospholipid syndrome. Although the prevalence of thromboembolic complications is low in both sclerotherapy and endovascular laser ablation, combination of both strategies might increase its incidence, even more in patients with unknown and uncontrolled hypercoagulable disorders.

(*Cite this article as:* Cifuentes J, Ulloa JH, Figueroa V, Ordoñez J, Montenegro A, Barragán C. Pulmonary embolic episode after hybrid treatment with endovascular laser ablation combined with polidocanol foam sclerotherapy. Acta Phlebol 2021;22:000-000. DOI: 10.23736/S1593-232X.21.00495-1)

KEY WORDS: Pulmonary embolism; Laser therapy; Sclerotherapy; Polidocanol.

Chronic venous insufficiency (CVI) affects approximately 20-30% of the adult population at any point of life.[1, 2] Hybrid treatment is a novel, minimally-invasive technique to successfully treat CVI, combining endovenous laser ablation (EVLA) and foam ultrasound guided sclerotherapy in the great saphenous vein (GSV).[3, 4] Open surgical treatment has been substituted by endovenous thermal ablation (EVTA) techniques, such as radiofrequency, EVLA, and chemical ablation with foam sclerotherapy.[2] Those are less morbid, ambulatory and require less time for the patient to recover the daily functionality. Nowadays, the National Institute for Health and Care Excellence (NICE) recommends EVLA as the first treatment option for varicosities in eligible patients.[5]

Given the proximity of the laser probe to the saphenofemoral junction, there is a potential risk of migration of thrombi from the superficial to the deep venous system. Venous thromboembolism (VTE), is a rare but potentially life-threatening complication of EVLA that in most cases is secondary to endovenous heat-induced thrombosis (E-HIT), which refers to the generation of thrombi in the distal portion of the obliterated vein and further embolization to the deep venous system and eventually the lungs.[2, 5] We present an uncommon case of pulmonary embolism (PE)

EUROPE MINERVA MEDICA

secondary to hybrid treatment, without a clear etiology, since there were no signs of superficial or deep venous thrombosis in the lower limbs.

The patient voluntarily accepted and signed the informed consent allowing us to use the information of the case and the diagnostic images.

Case report

We present the case of a 38 years-old woman with a 5-year history of CVI. She came to our office complaining of vesperal pain in both lower limbs, sensation of heaviness, swelling and varicosities, with predominance in the left leg. She underwent previous sclerotherapy with polidocanol foam two years ago, performed by a general physician to treat telangiectasias without clinical improvement. Initial physical examination showed varicosities in the posterior aspect of the left leg and popliteal fossa associated with distal edema (Figure 1). No skin pigmentation changes were observed, and the limb was classified as C3. A duplex scan of the left leg showed an average diameter of 12 mm and incompetence (reflux time >0.5 seconds) of the left GSV,[6] extending from the middle portion of the leg to the upper thigh, without compromising the saphenofemoral junction (SFJ). Hybrid treatment was scheduled and successfully performed. The technique consisted of placing an ultrasound-guided catheter in the infrageniculate GSV and through a port, inserting the laser fiber to ablate a 15 cm segment commencing 3 cm below the SFJ. Tumescent saline solution with lidocaine was previously injected surrounding the vein. We used an endovenous laser fiber of 1470 nm from ELVeS ®RadialTM® (Biolitec AG, Jena, Germany) with a LEED of 107 J/cm. Through the same port of access, 3 cc of 0.5% polidocanol foam prepared through the Tessari method with a physiologic gas mixture of CO_2/02 (70/30%), was injected in the infrageniculate segment of the GSV. The patient was released 30 minutes later with no apparent complications, prompt ambulation and compression stockings. All the recommendations of ambulation, compression stockings and early mobilization were clearly provided to the patient before leaving the office (Figure 1).

Figure 1.—Varicose veins in the popliteal fossa and posterior aspect of the left leg.

After 3 days, the patient developed a sharp chest pain, malaise and severe dyspnea while lying on the bed at home. Upon arrival at the ER, she was found with low oxygen blood levels (84%), body temperature of 38.3°C (100.94°F) and tachypnea (23 breaths per minute). Oxygen therapy was immediately initiated. A complete blood work was carried out, showing a D-dimer level of 2.3 µg/mL. PE was suspected and a chest computed tomography angiography was done, confirming the diagnosis of PE. Full anticoagulation was initiated, and the patient was admitted in the ICU. During the re-interrogation, the patient mentioned that her mother and grandmother died in the 6th decade of life, due to myocardial infarction and confirmed that she had no previous medical history. On physical examination realized by the vascular surgery team, we found apparently normal lower limbs, the left leg had no edema, erythema, tenderness or pain. A duplex showed absence of venous thrombosis in the whole deep territory of both legs, and the normal expectable changes after 3 days of the EVLA (Figure 2). The upper extremities had no signs of thrombosis and were not insonated.

The CTA showed a hanging thrombus in the pulmonary artery compatible with PE (Figure 3). The Pulmonary Embolism Severity Index (PESI)[7] was class II, low risk PE (1.7-3.5% 30 days mortality risk). A further blood work showed positive lupic anticoagulant, negative anticardiolipin antibodies (aCL) (5 GPL), and negative anti-ß2glycoprotein-1 (aß2GPI) antibodies, compatible with antiphospholipid syndrome (APS), the prevalence of which

PROOF MINERVA MEDICA

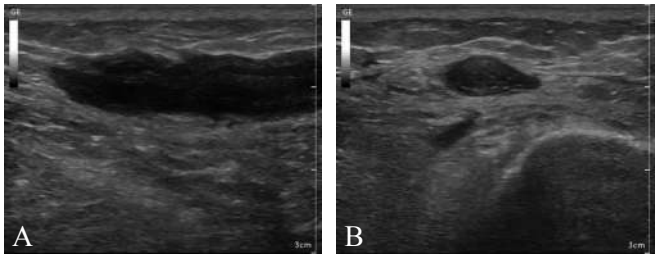

Figure 2.—A) Longitudinal view of the adequately occluded GSV supragenicular portion. B) Transverse view of the adequately occluded GSV supragenicular portion. The patient had the two characteristics of adequately occluded venous segments after EVLA: 1) absence of pain when applying pressure with the transducer; 2) intraluminal echoluscent images.

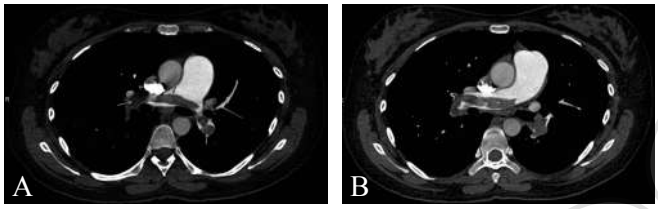

Figure 3.—Multidetector CT: axial view with soft tissue window. A) Acute thrombus cast in the trunk of the pulmonary artery projecting into both main arteries (saddle embolism) with partial occupation of their lumen. B) Thrombus extending to bilateral lobar branches with complete occupation of its lumen. Note the engorgement of the pulmonary artery trunk as signs of precapillary pulmonary hypertension.

is 0.0005% in the general population.[8] The patient was released with complete recovery 3 days later, after completing an extensive assessment by vascular medicine. At a 1-month follow-up visit, she had no symptoms related to the embolic episode, and referred improvement of her CVI symptoms (Figure 3).

Discussion

Pulmonary embolism secondary to EVLA and sclerotherapy has been reported with an incidence lower than 1%;[1-3, 9-12] with thromboembolic etiology as the most likely explanation. In those cases, thrombosis of the lower limbs was found.[1-3, 10, 11] Foam sclerotherapy induces fibrosis through direct contact with the endothelium of the vein; despite the objective of the treatment is the occlusion of the superficial venous system, migration into the deep system can occur and explain the PE of our patient. Morrison *et al.* studied this phenomenon and concluded that despite using maneuvers like balloon-tipped catheters, small volumes of foam, and elevation of the legs, none of those can completely prevent the migration of foam into the deep system.[13]

A study reported one case of PE, in a cohort of 977 patients who underwent foam sclerotherapy at 5 weeks of treatment.[14] The incidence of PE after EVLA is even lower. A study conducted in Japan found an incidence of PE after EVLA of 0.0067% (3 out of 43,203 patients).[1] Another article reported 0.07% in a sample of 1247 patients that underwent EVLA alone, and with hybrid treatment, the overall incidence was lower than 1%.[9] Moreover, a systematic review and meta-analysis of thrombotic events following EVTA of the GSV in more than 16,000 patients demonstrated that the incidence of PE is 0.1%.[5] Despite sclerotherapy and EVLA being considered as safe procedures,[15] vascular surgeons have to be aware of life-threatening complications such as cardiopathies, stroke, paradoxical embolism,[16, 17] and now PE.

Several variables have been proposed as risk factors for VTE after EVLA, including sex, age, obesity, vein diameter, Caprini Score, and catheter tip position, but none has shown to be a strong predictor.[1] The Society for Vascular Surgery and the American Venous Forum recommend that a lower extremity ultrasound should be performed 24 to 72 hours after EVLA to prevent VTE.[18] However, according to Jones and Kabnick,[19] clinical findings are more important than the ultrasound images. E-HIT might be an expected complication in this scenario, but the patient's ultrasound shows no thrombi in the GSV nor in the SFJ probably, because the E-HIT thrombus totally dislodged and embolized the lungs. Remarkably, a significant percentage of patients can have PE with no identifiable lower limbs source, as might be the case in this patient.

The influence of polidocanol or EVLA on the silent APS remains unknown, as well as the recommendations of anticoagulation in the context of patients with already diagnosed APS that are going to be scheduled for hybrid treatment. In that case, we recommend referring the patient to a vascular internist to evaluate the thromboembolic risk. The mechanism of action of EVLA has been studied *in vitro* by Proebstle *et al.* who found that the heat of the laser induces a local steam bubble formation, producing damage of the endothelium. However, the complete thrombotic occlusion takes place at least 1 day after the procedure, which explains why our patient debuted 3 days after the intervention.[20] The fact that the patient had been previously treated with polidocanol foam with no complications, suggests that combining foam sclerotherapy with EVLA slightly increases the risk of thromboembolic complications. Although this is not clearly reflected in the literature, our extensive review and our case support this hypothesis.

Conclusions

PE after either foam sclerotherapy or EVLA alone have demonstrated to have an extremely low incidence that might be slightly increased when performing hybrid treatment. A complete interview, including full medical records is mandatory, in order to anticipate possible at-risk patients for VTE. In this case, the association between the silent APS and PE is not clear and the most likely explanation for the thrombosis is E-HIT. Even so, the baseline hypercoagulable disorder of the patient per-se might have debuted with this episode of PE. Either way, the systemic effects of polidocanol need to be studied, and the question of whether or not to do screening for hypercoagulable disorders prior hybrid treatment still needs more studies to be answered and to determine its cost-effectiveness. Finally, vascular surgeons have to be aware of serious life-threatening complications of sclerotherapy and know their proper management.

References

1. Nemoto H, Mo M, Ito T, Inoue Y, Obitsu Y, Kichikawa K, *et al.*; Japanese Endovenous Ablation Committee for Varicose Veins. Venous thromboembolism complications after endovenous laser ablation for varicose veins and role of duplex ultrasound scan. J Vasc Surg Venous Lymphat Disord 2019;7:817–23.

2. Dermody M, Schul MW, O'Donnell TF. Thromboembolic complications of endovenous thermal ablation and foam sclerotherapy in the treatment of great saphenous vein insufficiency. Phlebology 2015;30:357–64.

3. Eklöf B, Rutherford RB, Bergan JJ, Carpentier PH, Gloviczki P, Kistner RL, *et al.*; American Venous Forum International Ad Hoc Committee for Revision of the CEAP Classification. Revision of the CEAP classification for chronic venous disorders: consensus statement. J Vasc Surg 2004;40:1248–52.

4. Nwaejike N, Srodon PD, Kyriakides C. Pulmonary Embolism following Endovenous Laser Ablation (EVLA) of the Great Saphenous Vein. J Radiol Case Rep 2008;2:9–12.

5. Healy DA, Kimura S, Power D, Elhaj A, Abdeldaim Y, Cross KS, *et al.* A Systematic Review and Meta-analysis of Thrombotic Events Following Endovenous Thermal Ablation of the Great Saphenous Vein. Eur J Vasc Endovasc Surg 2018;56:410–24.

6. Eberhardt RT, Raffetto JD. Chronic venous insufficiency. Circulation 2014;130:333–46.

7. Aujesky D, Perrier A, Roy PM, Stone RA, Cornuz J, Meyer G, *et al.* Validation of a clinical prognostic model to identify low-risk patients with pulmonary embolism. J Intern Med 2007;261:597–604.

8. Duarte-García A, Pham MM, Crowson CS, Amin S, Moder KG, Pruthi RK, *et al.* The Epidemiology of Antiphospholipid Syndrome: A Population-Based Study. Arthritis Rheumatol 2019;71:1545–52.

9. Mazayshvili K, Akimov S. Early complications of endovenous laser ablation. Int Angiol 2019;38:96–101.

10. Alder G, Lees T. Foam sclerotherapy. Phlebology 2015;30(Suppl):18–23.

11. Bruijninckx CM. Fatal pulmonary embolism following ultrasound-guided foam sclerotherapy combined with multiple microphlebectomies. Phlebology 2016;31:449–55.

12. Gillet JL, Guedes JM, Guex JJ, Hamel-Desnos C, Schadeck M, Lauseker M, *et al.* Side-effects and complications of foam sclerotherapy of the great and small saphenous veins: a controlled multicentre prospective study including 1,025 patients. Phlebology 2009;24:131–8.

13. Sadick N, Khilnani N, Morrison N. Practical Approach to the Management and Treatment of Venous Disorders. London: Springer; 2013.

14. Jia X, Mowatt G, Burr JM, Cassar K, Cook J, Fraser C. Systematic review of foam sclerotherapy for varicose veins. Br J Surg 2007;94:925–36.

15. Nwaejike N, Srodon PD, Kyriakides C. 5-years of endovenous laser ablation (EVLA) for the treatment of varicose veins—a prospective study. Int J Surg 2009;7:347–9.

16. Forlee MV, Grouden M, Moore DJ, Shanik G. Stroke after varicose vein foam injection sclerotherapy. J Vasc Surg 2006;43:162–4.

17. Calle ES, Pulido DE, Ulloa JH. Paradoxical embolism post-sclerotherapy using physiological gas. Acta Phlebol 2017;18:57–9.

18. Gloviczki P, Comerota AJ, Dalsing MC, Eklof BG, Gillespie DL, Gloviczki ML, *et al.*; Society for Vascular Surgery; American Venous Forum. The care of patients with varicose veins and associated chronic venous diseases: clinical practice guidelines of the Society for Vascular Surgery and the American Venous Forum. J Vasc Surg 2011;53(Suppl):2S–48S.

19. Jones RT, Kabnick LS. Perioperative duplex ultrasound following endothermal ablation of the saphenous vein: is it worthless? J Invasive Cardiol 2014;26:548–50.

20. Proebstle TM, Lehr HA, Kargl A, Espinola-Klein C, Rother W, Bethge S, *et al.* Endovenous treatment of the greater saphenous vein with a 940-nm diode laser: thrombotic occlusion after endoluminal thermal damage by laser-generated steam bubbles. J Vasc Surg 2002;35:729–36.

Conflicts of interest.—The authors certify that there is no conflict of interest with any financial organization regarding the material discussed in the manuscript.

Authors' contributions.—All authors read and approved the final version of the manuscript.

History.—Manuscript accepted: March 15, 2021. - Manuscript revised: March 9, 2021. - Manuscript received: February 1, 2021.

PROOF ONLY NOT FOR DISTRIBUTION